

## APPLICATION OF TUNICA VAGINALIS INTERPOSITIONAL FLAP IN REPAIR OF URETHROCUTANEOUS FISTULAE AFTER HYPOSPADIAS REPAIR

Ahmed Mohamed Ali

Plastic Surgery Departments, Faculty of Medicine, Zagazig University

### ABSTRACT

**Introduction and Objectives:** Urethrocutaneous fistula is the commonest complication of hypospadias surgery. The reported incidence varies from 2% to 17% in some series. As popularization of tubularized incised plate eliminate using of healthy dartos flap as interpositional layer in repair of fistula, tunica vaginalis can provide an excellent source for well vascularized, non fibrotic flap, being unaffected layer and away from primary site of hypospadias repair. **Patients and methods:** Eighteen patients with mean age 5.6yaers (range 3 to 8) with urethrocutaneous fistulae after repair of hypospadias were treated with our elected technique, for every patient a record of the numbers ,site, previous attempt for repair of the fistulae, original preoperative site of meatus, other penile complications ,the technique and date of hypospadias repair were reported. All operations were done under general anaesthesia and magnification (3.5x) .After identification of the site of fistulae they were excised sharply down to the urethral mucosa and closed transversely. The tunicas were approached through 2 cm transverse incision at penosecrotal junction for the distal fistulae, or through the same incision around the fistula if it was a proximal penile one and flaps from parietal layer of tunicas were harvested according to the location of fistulae then they were tunneled under the penile skin to the site of fistula where they were tacked to corporal tissue and the penile skin was closed. **Results:** Our patients were followed for a mean of 39 months (20-51) with no report of fistula recurrence in any patient , also complications such as testicular fixation, hematomas, urethral stricture, ventral chordee or cosmetic complication were not reported. **Conclusion:** using tunica vaginalis flap is a simple and reliable method for correction of post hypospadias fistulae

**Key word:** *hypospadias, urethraocutaneous, fistula, tunica vaginalis.*

### INTRODUCTION

Surgical techniques for hypospadias treatment have markedly improved during the last two decades<sup>(1)</sup>. Even after this improvement, urethrocutaneous fistulae still occur in 2-17% of hypospadias repair<sup>(2, 3)</sup>. Successful fistula repair depends on elimination of distal stricture and enriching the site of repair with well vascularized tissue<sup>(4, 5)</sup>. For recurrent fistulae repair, there is paucity of local tissues and the penile dartos being fibrotic, reducing the likelihood of its usage as a local flap for suture line coverage<sup>(5)</sup>. One option for fresh interposed tissue is tunica vaginalis flap(TVF) which was popularized by Snow et al.<sup>(6)</sup> In this study we will evaluate our method of repair of post hypospadias fistulae using tunica vaginalis flap.

### PATIENT AND METHOD

From June 2007 to February 2010 eighteen patients with mean age 5.6yaers (range 3 to 8) who had urthrocutaneous fistulas after hypospadias surgery were

treated with our elected technique. for every patient a record of the number, site, size (either  $\leq 2\text{mm}$  or  $> 2\text{mm}$ ) previous attempt for repair of the fistulae, original preoperative site of meatus, other penile complications, the technique and date of hypospadias repair, operative time was recorded . Tables1, 2, 3, 4 & 5.

**Table (1):** Number of fistulae

No. of fistulae	No. of patients (fistulae)
1	7 (7)
2	8 (16)
$\geq 3$	3 (10)
Number of fistulae	18(33)

**Table (2):** Site of fistulae

Site	No. of cases
Sub coronal	11
Mid Shaft	13
Proximal	9
Total	33

*Application Of Tunica Vaginalis Interpositional.....*

**Table (3):** Size of fistula

Size of fistula	Number
≤2mm	22
>2mm	10

**Table (4):** Previous attempts of repair

No previous trial	10
Failed previous trail	8

**Table (5):** Initial repair

Initial repair	No. of cases
TIP	6
Dackett	7
Mathieu	5
Total	18

The minimum time interval between fistulae repair and last surgery was six months. All patients received one dose of antibiotic (cephradine 30 mg/kg/day) one hour before surgery and continued on the same regimen postoperatively for one week.

*Surgical technique:* all operations were done under general anesthesia and magnification using 3.5x loop (Keeler), intraoperative identification of the proper site of fistulae was done by injection of methylene blue through cannula from the meatus while pressure was applied at perineum, urethrae were calibrated using 8F or 10F Nelton catheter to rule out stricture and left indwelling for one week postoperatively. If stricture was found during calibration gradual guarded dilation by dilators was done. All fistulae were excised sharply down to urethral mucosa and closed transversely with continuous subcuticular 6/0 polyglycolic acid (Vicryl) suture. (Fig.1)

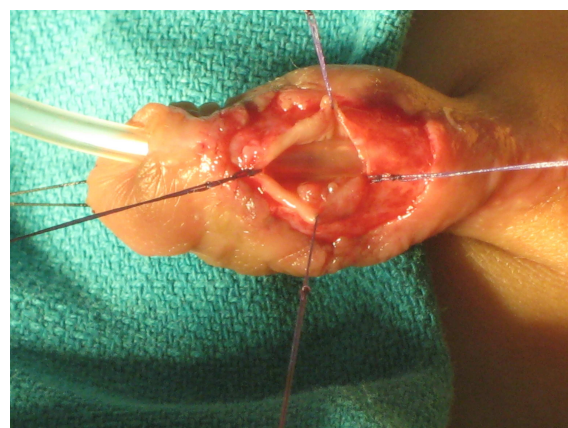
In 4 patients we did degloving of the penis due to presence of chordee that detected preoperatively and all fibrous bands were excised.

The tunicae were approached either through 2 cm transverse incision at penoscrotal junction or through the same incision around the fistula if it was proximal penile (Figs. 2&3). A flap from parietal layer of tunica vaginalis was harvested according the location of fistula (up to whole length of the spermatic cord)

then tunneled under the penile skin to the site of fistula where it was tacked to corporal tissue with mesothelial surface toward the skin. The penile skin was closed with 6/0 polyamid (Ethilone) interrupted suture (Fig. 4). The remaining part of tunica was closed with 4/0 polyglycolic acid and the scrotum was closed using 5/0 polyamid. The wounds were covered with bulky sterile gauze for two days to achieve hemostasis and to minimize postoperative edema. Aesthetic scoring for both penis and testis were obtained by reporting the opinion of four observers (other surgeon, nurse and both parents) as regards to the penile torque, testicular level and fixation; each observer gave a score of one for poor, two for satisfactory and three for good result for the three previous items. Summation of score was done and data were stratified into good > 30, satisfactory from 18 to 30 or poor outcome <18.

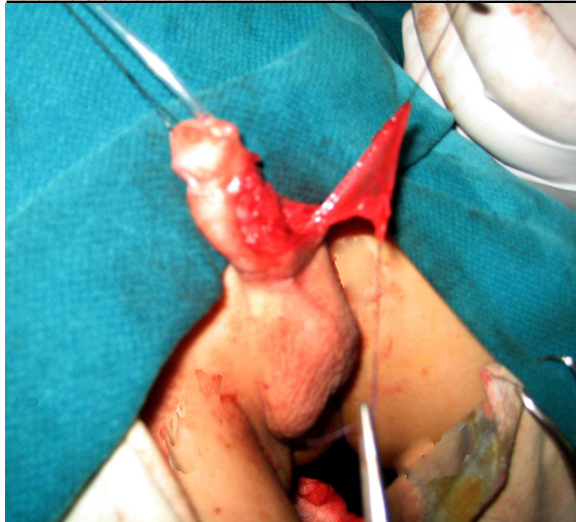**RESULTS**

Our patients were followed for a mean of 39 months (20-51) with no report of fistula recurrence in any patient (100% success rate). Complications such as urethral stricture, testicular hematomas, abscess or fixation were not noticed after surgery. Our operative time ranged from 45 to 60 minute (main 55 minute). Aesthetic results were rated as good (15 with good&3 with satisfactory) as there were no ventral chordee, penile torque or testicular level change.

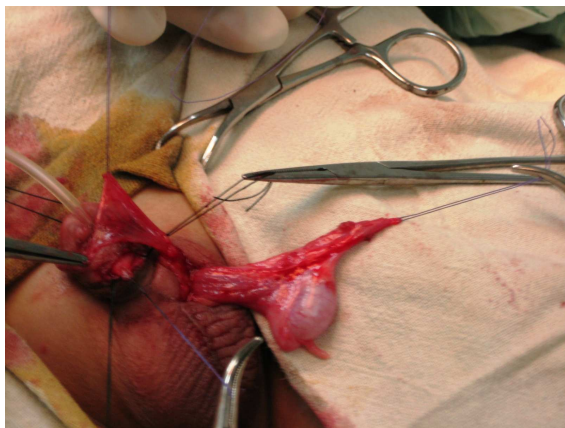


**Fig. (1):** Dissection of fistula

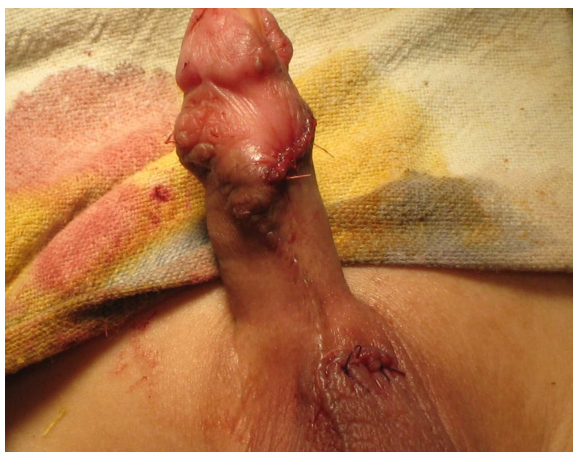
*Application Of Tunica Vaginalis Interpositional.....*



**Fig. (2):** Tunica flap elevation through fistula incision



**Fig. (3):** Tunical flap through penoscrotal incision



**Fig. (4):** Repaired fistula

**DISCUSSION**

Fistula formation is the commonest complication after hypospadias surgeries, and repair of these fistulas represents a challenge for the treating surgeons. several

surgical techniques have been described to solve this problem ranging from simple closure with success rate up to 80% to a more complex method with flap harvesting<sup>(7,8)</sup>, among these techniques TVF stands as simple and effective one<sup>(5)</sup>

The indications of using interposition flaps in fistulae repair is controversial, While Shankar et al. adopt restriction of tunica or dartos flaps application to the cases of multiple fistulae recurrence claiming that: at the first existence of fistula there is enough local tissue for repair while after several recurrence this local tissue become scanty and flaps application become mandatory, their opinion is supported by good (71%) success in their work and other studies which get up to 82% success rate<sup>(9,10)</sup> in primary fistulae repair without interposition flaps.<sup>(11)</sup> On the other side in many series flaps were used freely to ensure successful repair of fistulae,<sup>(5,12,13)</sup> moreover the indication for TVF was extended to involve prophylaxis against fistulae occurrence during initial hypospadias surgery.<sup>(14-17)</sup> As it was found that when the tunical flap was used, it can effectively prevent the occurrence of fistula.<sup>(4,12)</sup>

Tunica flap has many advantages promoting its use; as the tunica lies away from the operative field for hypospadias (penile shaft), its blood supply remains uninterrupted even in the conditions of multiple reoperations, operative access to tunica vaginalis is technically simple, the flap itself is thin so its passage through the penile shaft will not cause aesthetic problems.<sup>(6, 13, 16, 18)</sup>

All fistulae in our patients were completely healed; this high rate of success was noticed in many other studies that had up to 100% long lasting success.<sup>(5, 6, 13, 18)</sup>

We found that the site, size, number of the fistulae and previous attempt for repair have no impact on the success rate. We agree with Sunay et al who had the same findings<sup>(19)</sup>

Regarding the optimal time for fistula closure, we prefer to close a fistula at

*Application Of Tunica Vaginalis Interpositional.....*

least 6 months after the last surgery; this period allows the induration and inflammatory process to subside, we also wanted to see if some fistulae might close spontaneously in response to regular dilatation as the distal narrowing is an important factor for fistula formation.<sup>(12,20)</sup> However, Waterman et al reported no statistical significance in the success rate of fistula closure when performed less than versus more than 6 months after hypospadias repair<sup>(21)</sup>.

Prophylactic antibiotics were given to all patients to prevent infection which is considered as a one of the most common causes for recurrence. This protocol was advised by Lee et al.<sup>(22)</sup> especially in repeat procedures. In our work we gave attention to a well known helpful tools such as magnification to get the best results. Most recent studies stressed on magnification in hypospadias surgery and its sequel either with loop or microscope<sup>(5, 20)</sup>. We believe that loop magnification is adequate and more comfortable.

Our operative time was comparable to that mentioned by Routh et al. (45 minute) This relatively short time emphasized the simplicity of procedure<sup>(4,12)</sup>.

Although we did not notice any recurrence of fistula or penile torque during our follow up period (mean 39 months), Wood et al.<sup>(23)</sup> reported a recurrence of fistula even after two years and Pattaras and Rushton<sup>(24)</sup> reported penile torque after years of tunica flap repair.

Absence of testicular complication in our patients points to the safety of this procedure. This safety was noticed in the work of Sow, as only one patient developed scrotal hematoma and another one had abscess among eighty nine patients underwent flap harvesting.<sup>(6)</sup>

**REFERENCE**

1. Belman AB. Hypospadias and chordee. In: Clinical Pediatric Urology. Edited by Belman AB, King LR, Kramer SA. 4<sup>th</sup> edn. London: Martin Dunitz, 2002, p.1069
2. Rushton HG, Belman AB. The split prepuce in situ onlay hypospadias repair. J Urol 1998; 160: 1134
3. Aposa HS. New concepts in the management of hypospadias and its complications. Ann R Coll Surg Engl 1998; 80: 161
4. Routh JC, Wolpert JJ, Reinberg Y. Tunneled Tunica Vaginalis Flap for Recurrent Urethrocutaneous Fistulae. Advances in Urology 2008:1-3
5. Landau EH, Gofrit ON, Meretyk S, Katz G, Golijanin D, Shenfeld OZ, Pode D. Outcome analysis of tunica vaginalis flap for the correction of recurrent urethrocutaneous fistula in children. The Journal of Urology 2003; 170:1596-9
6. Snow BW, Cartwright PC, Unger K. Tunica vaginalis blanket wrap to prevent urethrocutaneous fistula: an 8-year experience. J Urol 1995; 153: 472
7. Awad MS: A simple novel technique [PUIT] for closure of urethrocutaneous fistula after hypospadias repair: Preliminary results. Indian Journal of Plastic Surgery 2005; 38 (2):114-8.
8. Cimador M, Castagnetti M, De Grazia E. Urethrocutaneous fistula repair after hypospadias surgery. BJU International 2003; 92(6): 621 –3
9. Latifoglu O, Yavuzer R, Unal S, Cavusoglu T, Atabay K. Surgical treatment of urethral fistulas following hypospadias repair. Ann Plast Surg 2000; 44(4): 381-6
10. Redman J F. Results of undiverted simple closure of 51 urethrocutaneous fistulas in boys. Urology 1993; 41: 369
11. Shankar KR, Losty PD, Hopper M, Wong L, Rickwood AMK. Outcome of hypospadias fistula repair. BJU International 2002; 89 (1):103 – 5
12. Routh JC, Wolpert JJ, Reinberg Y. Tunneled Tunica Vaginalis Flap is an Effective Technique for Recurrent Urethrocutaneous Fistulas Following Tubularized Incised Plate Urethroplasty. J Urol 2006; 176: 1578-81
13. Singh RB, Pavithran NM. Tunica vaginalis interposition flap in the closure of massive disruption of the neourethral tube (macro urethrocutaneous fistulae). Pediatric Surgery International 2004; 20 (6): 464–6.

*Application Of Tunica Vaginalis Interpositional.....*

14. Handoo YR. Role of tunica vaginalis interposition layer in hypospadias surgery. Indian J Plast Surg 2006; 39:152-6
15. Chatterjee US, Mandal MK, Basu S, Das R, Majhi T . Comparative study of dartos fascia and tunica vaginalis pedicle wrap for the tubularized incised plate in primary hypospadias repair. BJU Int. 2004; 94(7):1102-4.
16. Kirkali Z. Tunica vaginalis: an aid in hypospadias surgery. Br J Urol. 1990; 65(5):530-2
17. Tavakkoli Tabassi K, Mohammadi S. Tunica vaginalis flap as a second layer for tubularized incised plate urethroplasty. Urol J. 2010; 7(4):254-7.
18. Xue WY, Qu CB, Wang XL, Zhang FX, Kang CS. The application of tunicsa vaginalis flap in urethral repair. Zhonghua Zheng Xing Wai Ke Za Zhi 2007; 23: 45-7.
19. Sunay M, Dadali M, Karabulut A, Emir L, Erol D. Our 23-Year Experience in Urethrocutaneous Fistulas Developing After Hypospadias Surgery. Urology 2007; 69 (2): 366–8.
20. Voges GE, Riedmiller H, Hohenfellner R. Tunica vaginalis free grafts for closure of urethrocutaneous fistulas. Urologia Internationalis 1990; 45 (2): 88–91
21. Waterman BJ, Renschler T, Cartwright PC, Snow BW, DeVries CR. Variables in successful repair of urethrocutaneous fistula after hypospadias surgery. J Urol 2002; 168: 726.
22. Lee YC, Huang CH, Chou YH, Lin CH, Wen-Jeng Wu WJ. Outcome of hypospadias reoperation based on preoperative antimicrobial prophylaxis. Kaohsiung J Med Sci 2005; 21 (8): 351-6
23. Wood HM, Kay R, Angermeier KW, Ross JH. Timing of the presentation of urethrocutaneous fistulas after hypospadias repair in pediatric patients. J Urol 2008; 180(4 Suppl):1753-6. Epub 2008 Aug 21
24. Pattaras JG, Rushton HG. Penile torque after the use of tunica vaginalis blanket wrap as an aid in hypospadias repair. Journal of Urology 1999; 161 (3): 934–5.